



International
Labour
Office
Geneva

GUIDELINES FOR THE USE OF THE ILO INTERNATIONAL CLASSIFICATION OF RADIOGRAPHS OF PNEUMOCONIOSES

(REVISED EDITION 2011)

Occupational
Safety and Health
Series

22

OCCUPATIONAL SAFETY AND HEALTH SERIES No. 22 (Rev. 2011)

GUIDELINES FOR THE USE OF THE ILO INTERNATIONAL CLASSIFICATION OF RADIOGRAPHS OF PNEUMOCONIOSES

Revised edition 2011

INTERNATIONAL LABOUR OFFICE · GENEVA

Copyright © International Labour Organization 2011
First published 2011

Publications of the International Labour Office enjoy copyright under Protocol 2 of the Universal Copyright Convention. Nevertheless, short excerpts from them may be reproduced without authorization, on condition that the source is indicated. For rights of reproduction or translation, application should be made to ILO Publications (Rights and Permissions), International Labour Office, CH-1211 Geneva 22, Switzerland, or by email: pubdroit@ilo.org. The International Labour Office welcomes such applications.

Libraries, institutions and other users registered with reproduction rights organizations may make copies in accordance with the licences issued to them for this purpose. Visit www.ifro.org to find the reproduction rights organization in your country.

ILO
Guidelines for the use of the ILO International Classification of Radiographs of Pneumoconioses
Revised edition 2011
Geneva, International Labour Office, 2011

pneumoconiosis/medical examination/standardization

15.04.2

1 v. (Occupational safety and health series; 22 (Rev.2011))

ISBN 978-92-2-124541-4 (print)

ISBN 978-92-2-124542-1 (pdf)

ISBN 978-92-2-125049-4 (complete set)

ILO Cataloguing in Publication Data

The designations employed in ILO publications, which are in conformity with United Nations practice, and the presentation of material therein do not imply the expression of any opinion whatsoever on the part of the International Labour Office concerning the legal status of any country, area or territory or of its authorities, or concerning the delimitation of its frontiers.

The responsibility for opinions expressed in signed articles, studies and other contributions rests solely with their authors, and publication does not constitute an endorsement by the International Labour Office of the opinions expressed in them.

Reference to names of firms and commercial products and processes does not imply their endorsement by the International Labour Office, and any failure to mention a particular firm, commercial product or process is not a sign of disapproval.

ILO publications and electronic products can be obtained through major booksellers or ILO local offices in many countries, or direct from ILO Publications, International Labour Office, CH-1211 Geneva 22, Switzerland. Catalogues or lists of new publications are available free of charge from the above address, or by email: pubvente@ilo.org

Visit our website: www.ilo.org/publns

Contents

| | |
|--|------------|
| Foreword to the 2011 revised edition | vii |
| Foreword to the 2000 revised edition | ix |
| 1. Introduction | 1 |
| 2. General instructions | 2 |
| 3. Specific instructions for use of the Complete Classification | 3 |
| 3.1. Technical quality | 3 |
| 3.2. Parenchymal abnormalities | 3 |
| 3.3. Pleural abnormalities | 6 |
| 3.4. Symbols | 8 |
| 3.5. Comments | 9 |
| 4. Specific instructions for the use of the Abbreviated Classification | 10 |
| 5. Using the ILO Classification | 12 |
| 6. Using the ILO Classification to classify digital radiographic images of the chest | 14 |
| 7. Appendices | 18 |
| A. A note on technical quality for chest radiographs of dust-exposed workers | 19 |
| B. Reading sheets | 21 |
| C. Description of standard radiographs | 27 |
| D. Diagrams | 35 |
| E. Summary of details of the ILO (2000) International Classification of Radiographs of Pneumoconioses | 39 |
| F. Participants in ILO-convened meetings leading to the revised (2000 and 2011) editions of the Classification | 43 |

Foreword to the Revised Edition (2011)

This revised (2011) edition of the *Guidelines for the use of the ILO International Classification of Radiographs of Pneumoconioses* extends the applicability of the Classification to digital radiographic images of the chest, as described in a new chapter 6 (page 14).

Chapters 1 through 5 are identical to those that appeared in the preceding (2000) edition of the *Guidelines*. That text remains applicable as written for classifying conventional film-screen radiographs and the associated sets of ILO standard radiographs remain available from the ILO.

Note that in chapter 6:

- the word “image” refers to both film-based and soft copy images;
- “ILO standard chest image” refers to both electronic and film-based versions of standard images provided by the ILO;
- “ILO 2000” or “ILO standard radiograph” refer to standard films distributed by the ILO since the year 2000;
- “ILO 2011-D” or “ILO Standard Digital Image” refer to images derived from the ILO (2000) standard radiographs that have been distributed by the ILO in electronic format since the year 2011.

The ILO is grateful to 14 experts from seven countries who participated in a two-day scientific meeting in Rockville, Maryland, United States, on 13 and 14 March 2008 (see Appendix F). Their enthusiastic and intensive work during the meeting and in preceding months enabled publication of this revised (2011) edition of the *Guidelines for the use of the ILO International Classification of Radiographs of Pneumoconioses*.

Foreword to the Revised Edition (2000)

Over the last seven decades the International Labour Office (ILO) has promoted discussion and published a series of guidelines on how to classify chest radiographs of persons with pneumoconioses. The goals have been to standardize classification methods and facilitate international comparisons of data on pneumoconioses, epidemiological investigations and research reports. This revised edition of the ILO's International Classification of Radiographs of Pneumoconioses is a further effort towards these objectives. Based on the principles that governed the development of earlier editions of the Classification (those of 1950, 1958, 1968, 1971 and 1980), it refers to radiological appearances seen in all types of pneumoconioses. The description of the scheme in this revision of the *Guidelines* is more concise than previously. Some ambiguities in earlier editions have been clarified further, and the conventions for classifying pleural abnormalities have been revised. The changes are based on a comprehensive review of experience in using the preceding (1980) edition of the Classification.

The ILO initiated the review process in November 1989 at a meeting of 11 experts from seven countries. Participants were asked to advise on the kind of changes to the scheme that might be desirable, and to reconsider the suitability of the standard radiographs that accompanied the 1980 edition. Some parts of the *Guidelines* were identified as requiring revision, but the importance of continuity in the Classification was re-emphasized. With this in mind, it was agreed that the set of standard radiographs that were distributed with the 1980 edition should be retained, although it was recognized that the technical quality of many of them was inferior to that available with modern equipment and techniques. Participants in the meeting also suggested that the number of radiographs included in the complete set of standards (22) might be usefully reduced by reproducing critical parts from some of them onto quadrant sections of full-size radiographs. It was agreed, however, that it was necessary to verify that such a reform would not, in itself, result in a change in the way that radiographs of persons exposed to dust were classified. A controlled trial was therefore arranged by the ILO and the Division of Respiratory Disease Studies of the United States National Institute for Occupational Safety and Health (NIOSH). This involved 40 physicians, working at specialized clinical and research centres in ten countries (see Appendix F).

Results from the trial showed that the proposed modification to the ILO standard radiographs, involving reproduction of sections from 15 of the ILO (1980) standards onto five new "quadrant" radiographs, would not increase variability between readers, and might improve the reproducibility of small-opacity profusion classification in some respects, but could also reduce slightly the frequency with which some readers identify large opacities. Use of the standards containing the quadrant radiographs was associated with an increase in the frequency with which some readers described the shapes of the small opacities that they saw as predominantly irregular, rather than rounded. It was

concluded, however, that the effects found were unlikely to be distinguishable from inter- and intra-reader variability in most occupational health survey situations.¹

In October 1997 more than 200 participants in the Ninth International Conference on Occupational Respiratory Diseases in Kyoto, Japan, attended an ILO-convened Working Group on the Classification. That meeting recommended further work on the development of quadrant or sectional composite radiographs and improved techniques for standard radiograph reproduction prior to the introduction of revised standard radiographs. A smaller group of experts attending the same conference then considered in detail a draft revised text of the *Guidelines* to the Classification. Discussion of this draft continued at a further meeting in March 1998 at the offices of the American College of Radiology (ACR) in Reston, Virginia, and was concluded on 26 October 2000 at the ILO Branch Office in Washington, DC. Participants in the latter meeting also compared two types of new copies of several sets of ILO (1980) standard radiographs, of sectional quadrant radiographs that had been used in the international trial, and of a newly prepared composite radiograph illustrating pleural abnormalities. The new copies that were under review were produced from earlier copies, both by standard film copying methods and by improved techniques from digitized versions of the earlier copies. The experts preferred the copies made from the digitized versions, and they recommended the use of this technology and the associated reproduction process for producing future copies of ILO standard radiographs. The individuals who attended the various ILO-convened meetings concerned with the revision of the Classification are listed in Appendix F.

The ILO (2000) International Classification of Radiographs of Pneumoconioses is accompanied by two sets of standard radiographs, as described in Appendix C. Both sets are available from the ILO. The first (“Complete”) Set consists of 22 radiographs. Twenty of them are new copies from digitized full-size standard radiographs distributed previously with the 1980 edition of the ILO Classification. A further radiograph illustrates u/u-sized irregular opacities. Three quadrants of this radiograph reproduce the sections of the composite radiograph that was used in 1980 to depict increasing profusion of u/u-sized irregular opacities; the fourth quadrant illustrates subcategory 0/0. A new composite radiograph is provided to illustrate pleural abnormalities.

The “Quad” Set consists of 14 radiographs. Nine of them are the most commonly used standards from the Complete Set. The other five reproduce (quadrant) sections of the remaining radiographs in the Complete Set.

The development of this revised (2000) edition of the *Guidelines for the Use of the ILO International Classification of Radiographs of Pneumoconioses* has been made possible by virtue of intensive and sustained activity on the part of many individuals and organizations. Some of them are named in Appendix F. Others, too numerous to list, provided valuable comments and suggestions in writing and by contributing to discussions at various scientific meetings, including four ILO international conferences on pneumoconioses and occupational lung diseases (Bochum, Germany, 1983; Pittsburgh, Pennsylvania, 1987; Prague, 1992; and Kyoto, 1997). The ILO wishes to express its sincere thanks to all concerned, and to acknowledge gratefully the active assistance from the Committee on Pneumoconiosis (previously the Task Force on Pneumoconiosis) of the American College of Radiology (ACR), the United States National Institute for Occupational Safety and Health (NIOSH), the Rosai Hospital for Silicosis in Japan, the WHO

¹ A trial of additional composite standard radiographs for use with the ILO International Classification of Radiographs of Pneumoconioses, NIOSH Report No. HETA 93-0340, July 1997, available from National Technical Information Service (NTIS), 5825 Port Royal Road, Springfield, Virginia 2216, United States. A shorter report has been published: “New composite (“Quadrant”) standard films for classifying radiographs of pneumoconioses”, in *Industrial Health*, Vol. 36, No. 4, Oct. 1998, pp. 380–383.

Collaborating Centre for Radiological Education in Sweden, the Finnish Institute of Occupational Health, the German Committee for Diagnostic Radiology of Occupational and Environmental Diseases, and the Institute for Occupational and Social Medicine of the University of Cologne. Continuing use of the ILO International Classification of Radiographs of Pneumoconioses will contribute further to the protection of the health of workers in dusty occupations.

Introduction

Scope of the Classification

The Classification provides a means for describing and recording systematically the radiographic abnormalities in the chest provoked by the inhalation of dusts. It is used to describe radiographic abnormalities that occur in any type of pneumoconiosis and is designed for classifying only the appearances seen on postero-anterior chest radiographs. Other views and imaging techniques may be required for clinical assessment of individuals, but the ILO International Classification has not been designed to code such findings.

Object of the Classification

The object of the Classification is to codify the radiographic abnormalities of the pneumoconioses in a simple, reproducible manner. The Classification neither defines pathological entities nor takes into account working capacity. It does not imply legal definitions of pneumoconioses for compensation purposes and does not set or imply a level at which compensation is payable.

Uses of the Classification

The Classification is used internationally for epidemiological research, for screening and surveillance of those in dusty occupations, and for clinical purposes. Use of the scheme may lead to better international comparability of data concerning the pneumoconioses.

Standard radiographs and written definitions

The Classification consists of a set of standard radiographs and this text, with the accompanying footnotes. These footnotes are intended to reduce ambiguity and are based on experience with earlier editions of the ILO Classification. In some parts of the scheme, the standard radiographs take precedence over the written definitions. The text makes it clear when this is so.

General instructions

No radiographic features are pathognomonic of dust exposure. Some radiographic features that are unrelated to inhaled dust may mimic those caused by dust. Readers may differ about the interpretation of such appearances.

In epidemiological studies, therefore, the study protocol will usually require that all appearances described in these *Guidelines* and seen on the standard radiographs are to be classified. Symbols must always be used and appropriate Comments must be reported.¹

When the Classification is used for some clinical purposes, the protocol may require that medical readers classify only those appearances which the reader believes or suspects to be pneumoconiotic in origin. Symbols must always be used and appropriate Comments must be reported.¹

¹ See sections 3.4 and 3.5.

Specific instructions for use of the Complete Classification

3.1. Technical quality^{2,3}

Four grades of technical quality are used :

1. Good.
2. Acceptable, with no technical defect likely to impair classification of the radiograph for pneumoconiosis.
3. Acceptable, with some technical defect but still adequate for classification purposes.
4. Unacceptable for classification purposes.

If technical quality is not grade 1, a Comment must be made about the technical defects.

3.2. Parenchymal abnormalities

Parenchymal abnormalities include both small opacities and large opacities.

Small opacities

Small opacities are described by *profusion*, *affected zones of the lung*, *shape (rounded or irregular)* and *size*. The order of identifying and recording the presence or absence of these findings while classifying a radiograph is left to the reader's preference.

Profusion

The *profusion* of small opacities refers to the concentration of small opacities in affected zones of the lung. The category of profusion is based on comparisons with the standard radiographs. For profusion the written descriptions are a guide, but the standard

² Appendix A emphasizes the importance of good radiographic quality for the interpretation of chest radiographs. It is essential to produce radiographs that show clearly both the parenchyma and the pleural characteristics. For clinical purposes, special views or techniques may also be required. When it is not possible to replace a grade 3 radiograph by a better one, more details about technical defects should be recorded.

³ The standard radiographs are not to be considered in determining technical quality of the subject radiographs. The standard radiographs were chosen to demonstrate the radiographic features of the pneumoconioses, rather than to demonstrate technical quality.

radiographs take precedence. Four categories are defined by the standard radiographs. Profusion is classified into one of 12 ordered subcategories, which are represented symbolically as follows.⁴

| | | | | | | | | | | | | |
|---|----------|-----|-----|----------|-----|-----|----------|-----|-----|----------|-----|-----|
| Increasing profusion of small opacities → | | | | | | | | | | | | |
| Categories | 0 | | | 1 | | | 2 | | | 3 | | |
| Subcategories | 0/- | 0/0 | 0/1 | 1/0 | 1/1 | 1/2 | 2/1 | 2/2 | 2/3 | 3/2 | 3/3 | 3/+ |

Category **0** refers to the absence of small opacities or the presence of small opacities that are less profuse than category **1**.

Classification of a radiograph using the 12-subcategory scale is performed as follows. The appropriate category is chosen by comparing a subject radiograph with standard radiographs that define the levels of profusion characteristic of the centrally placed subcategories (**0/0**, **1/1**, **2/2**, **3/3**) within these categories. The category is recorded by writing the corresponding symbol followed by an oblique stroke, i.e. **0/** , **1/** , **2/** , **3/**. If no alternative category was seriously considered, the radiograph is classified into the central subcategory, i.e. **0/0**, **1/1**, **2/2**, **3/3**. For example, a radiograph that shows profusion which is considered to be similar to that shown on a subcategory **2/2** standard radiograph, i.e. neither category **1** nor **3** was seriously considered as an alternative, would be classified as **2/2**. However, subcategory **2/1** refers to a radiograph with profusion of small opacities judged to be similar in appearance to that depicted on a subcategory **2/2** standard radiograph, but category **1** was seriously considered as an alternative before deciding to classify it as category **2**.

The standard radiographs provide examples of appearances classifiable as subcategory **0/0**. Subcategory **0/0** refers to radiographs where there are no small opacities, or if a few are thought to be present, they are not sufficiently definite or numerous for category **1** to have been seriously considered as an alternative. Subcategory **0/1** is used for radiographs classified as category **0** after having seriously considered category **1** as an alternative. Subcategory **1/0** is used for radiographs classified as category **1** after having seriously considered category **0** as an alternative. If the absence of small opacities is particularly obvious, then the radiograph is classified as subcategory **0/-**.

A radiograph showing profusion much greater than that depicted on a subcategory **3/3** standard radiograph is classified as subcategory **3/+**.

⁴ The 12 subcategories refer only to the profusion of small opacities. Profusion, including references to subcategories **0/-** or **0/0** when appropriate, must always be recorded, irrespective of any other abnormalities that may be present. Conversely, when other abnormalities are seen, their presence must also be recorded, irrespective of whether any small opacities are present. The subcategories are arbitrary divisions of an underlying continuum of increasing profusion of small opacities. Those divisions are defined by the standard radiographs, together with the instructions for their use. The validity of the classification procedure to represent this continuum has been demonstrated in studies of relationships between results obtained by using the ILO Classification and (a) indices of cumulative exposures to various dusts; (b) the dust content of coalminers' lungs post mortem; (c) mortality of asbestos workers and coalminers; and (d) pathological appearances of coalminers' lungs post mortem.

Affected zones

The zones in which the opacities are seen are recorded. Each lung field is divided into three zones (upper, middle, lower) by horizontal lines drawn at approximately one-third and two-thirds of the vertical distance between the lung apices and the domes of the diaphragm.

The overall profusion of small opacities is determined by considering the profusion as a whole over *affected zones* of the lungs. When there is a marked (three subcategories or more) difference in profusion in different zones of the lungs, then the zone or zones showing the marked lesser degree of profusion is/are ignored for the purpose of classifying the overall profusion.⁵

Shape and size

For shape and size, the written definitions are a guide, and the standard radiographs take precedence. The shape and size of small opacities are recorded. Two kinds of shape are recognized: rounded and irregular. In each case, three sizes are differentiated.

For small rounded opacities, the three size ranges are denoted by the letters **p**, **q** and **r**, and are defined by the appearances of the small opacities on the corresponding standard radiographs. These illustrate:

- p**-opacities with diameters up to about 1.5 mm;
- q**-opacities with diameters exceeding about 1.5 mm and up to about 3 mm;
- r**-opacities with diameters exceeding about 3 mm and up to about 10 mm.


The three size ranges of small irregular opacities are denoted by the letters **s**, **t** and **u**, and are defined by the appearances of the small opacities on the corresponding standard radiographs. These illustrate:

- s**-opacities with widths up to about 1.5 mm;
- t**-opacities with widths exceeding about 1.5 mm and up to about 3 mm;
- u**-opacities with widths exceeding about 3 mm and up to about 10 mm.

⁵ A "marked (three subcategories or more) difference" in profusion in different zones of the lung is present when there are two or more subcategories of profusion *between* the zone (or zones) of the lowest profusion *and* the zone (or zones) of the highest profusion. For example, if a subject radiograph displays zones with profusion levels **1/1**, **1/2**, **2/1** and **2/2**, the overall profusion is determined by ignoring the zone with profusion level **1/1**, since two or more subcategories (**1/2**, **2/1**) are between that zone and the zone of the highest profusion (**2/2**). The overall profusion, therefore, is determined by considering only the affected zones showing profusion levels **1/2**, **2/1** and **2/2**, since there is only one subcategory of profusion (**2/1**) between profusion levels **1/2** and **2/2**.

Example 1

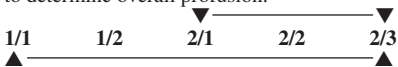
Only one intervening subcategory between the zones of lowest (**1/2**) and highest (**2/2**) profusion; use all three to determine overall profusion.



There are two intervening subcategories between the zones of lowest (**1/1**) and highest (**2/2**) profusion; ignore **1/1** to determine overall profusion.

Example 2

Only one intervening subcategory between the zones of lowest (**2/1**) and highest (**2/3**) profusion; use all three to determine overall profusion.



There are three intervening subcategories between the zones of lowest (**1/1**) and highest (**2/3**) profusion; ignore **1/1** and **1/2**; use **2/1**, **2/2**, **2/3** to determine overall profusion since there is only one subcategory between **2/1** and **2/3**.

All zones in which opacities are seen are recorded, irrespective of whether some are later ignored in determining overall profusion.

Two letters must be used to record shape and size. Thus, if the reader considers that all, or virtually all, opacities seen are of one shape and size, then this is noted by recording the letter twice, separated by an oblique stroke (for example **q/q**). If, however, significant numbers of another shape or size are seen, then this is recorded by writing a different letter after the oblique stroke (for example **q/t**); **q/t** would mean that the predominant small opacities are rounded and of size **q**, but that there are significant numbers of small irregular opacities present of size **t**. In this way, any combination of small opacities may be recorded.⁶ When small opacities of different shapes and/or size are seen, the letter for the predominant shape and size (primary) is recorded before the oblique stroke, while the letter for the less frequently occurring shape and size (secondary) is recorded after the oblique stroke.

Large opacities

A large opacity is defined as an opacity having the longest dimension exceeding 10 mm. Categories of large opacities are defined below. These definitions take precedence over the examples of large opacities illustrated on standard radiographs.

- Category A** One large opacity having the longest dimension up to about 50 mm, or several large opacities with the sum of their longest dimensions not exceeding about 50 mm.
- Category B** One large opacity having the longest dimension exceeding 50 mm but not exceeding the equivalent area of the right upper zone, or several large opacities with the sum of their longest dimensions exceeding 50 mm but not exceeding the equivalent area of the right upper zone.
- Category C** One large opacity which exceeds the equivalent area of the right upper zone, or several large opacities which, when combined, exceed the equivalent area of the right upper zone.

3.3. Pleural abnormalities

Pleural abnormalities are divided into pleural plaques (localized pleural thickening), costophrenic angle obliteration and diffuse pleural thickening.

Pleural plaques (localized pleural thickening)

Pleural plaques represent localized pleural thickening, generally of the parietal pleura. Pleural plaques may be seen on the diaphragm, on the chest wall (in-profile or face-on), and at other sites. At times, they are recognized only by their calcification. Pleural plaques are recorded as absent or present. If present on the chest wall, they are recorded as in-profile or face-on, and separately for the right and left sides. A minimum width of about 3 mm is required for an in-profile plaque to be recorded as present.^{7,8}

⁶ See Appendix E for possible combinations.

⁷ The measurement of width is made from the innermost margin of the rib to the innermost sharp margin of the plaque at the pleural-parenchymal boundary.

⁸ If more detailed measurement of width is required for a particular study, three categories may be used:
a – about 3 mm up to about 5 mm;
b – about 5 mm up to about 10 mm;
c – over about 10 mm.

Site, calcification and extent of pleural plaques are recorded separately for the right and for the left side of the chest. The written guidelines describing these features take precedence over the examples provided on the standard radiograph.

Site

The sites (locations) of pleural plaques include chest wall, diaphragm and other sites. Other sites include the mediastinal pleura in the para-spinal or para-cardiac locations. The presence or absence of pleural plaques is recorded for all sites, and separately for the right and for the left sides.

Calcification

Radiographic images of pleural plaques may include recognizable areas of calcification. The presence or absence of calcification is recorded for all plaques, and separately for the right and for the left sides. When calcification is seen, a plaque is also recorded as present at that site.

Extent

Extent is not recorded for plaques on the diaphragm or at other sites. It is recorded only for plaques along the chest wall, and is combined for both in-profile and face-on varieties. Extent is defined in terms of the total length of involvement with respect to the projection of the lateral chest wall (from the apex to the costophrenic angle) on the postero–anterior chest radiograph :

- 1 = total length up to one-quarter of the projection of the lateral chest wall ;
- 2 = total length exceeding one-quarter and up to one-half of the projection of the lateral chest wall ;
- 3 = total length exceeding one-half of the projection of the lateral chest wall.

Costophrenic angle obliteration

Costophrenic angle obliteration is recorded as either present or absent, separately for the right and for the left side. The lower limit for recording costophrenic angle obliteration is defined by the standard radiograph showing profusion subcategory **1/1 t/t**. If the pleural thickening extends up the lateral chest wall from the obliterated costophrenic angle, the thickening should be classified as diffuse pleural thickening. Costophrenic angle obliteration may occur without diffuse pleural thickening.

Diffuse pleural thickening

Diffuse pleural thickening historically has referred to thickening of the visceral pleura. The radiological distinction between parietal and visceral pleural thickening is not always possible on a postero–anterior radiograph.

For the purpose of the ILO (2000) Classification, diffuse pleural thickening extending up the lateral chest wall is recorded *only* in the presence of, and in continuity with, an obliterated costophrenic angle. Diffuse pleural thickening is recorded as absent or present along the chest wall. If present, it is recorded as in-profile or face-on, and separately for the right and the left side. Its extent is recorded in the same manner as for pleural plaques. A minimum width of about 3 mm is required for in-profile diffuse pleural

thickening to be recorded as present. If detailed measurement of its width is required for a particular study, see the comment provided in footnote 8.

Calcification and extent of diffuse pleural thickening on the chest wall are recorded separately for the right and for the left side (see guidelines for pleural plaques). The pleura may often be seen at the apex of the lung and should not be recorded as part of diffuse pleural thickening of the chest wall.

3.4. Symbols

Symbols to record radiographic features of importance are listed below. Their use is relevant because they describe additional features related to dust exposure and other aetiologies. Use of these symbols is obligatory.⁹

Some of the symbols imply interpretations, rather than just descriptions, of what is seen on the radiograph. A postero–anterior chest radiograph on its own may not be sufficient to justify definitive interpretation; therefore, each of the following definitions of symbols assumes an introductory qualifying word or phrase such as “changes indicative of”, or “opacities suggestive of”, or “suspect”.

The symbols are:

| | |
|-----------|--|
| aa | atherosclerotic aorta |
| at | significant apical pleural thickening (see Appendix D) |
| ax | coalescence of small opacities ¹⁰ |
| bu | bullae |
| ca | cancer: thoracic malignancies excluding mesothelioma |
| cg | calcified non-pneumoconiotic nodules (e.g. granuloma) or nodes |
| cn | calcification in small pneumoconiotic opacities |
| co | abnormality of cardiac size or shape |
| cp | cor pulmonale |
| cv | cavity |
| di | marked distortion of an intrathoracic structure |
| ef | pleural effusion |
| em | emphysema |
| es | eggshell calcification of hilar or mediastinal lymph nodes |
| fr | fractured rib(s) (acute or healed) |
| hi | enlargement of non-calcified hilar or mediastinal lymph nodes |
| ho | honeycomb lung |
| id | ill-defined diaphragm border ¹¹ |
| ih | ill-defined heart border ¹² |
| kl | septal (Kerley) lines |
| me | mesothelioma |

⁹ Inclusion of this information in statistical analyses of results may help to explain otherwise inexplicable variation between readers in their classifications of the same radiographs.

¹⁰ The symbol **ax** represents coalescence of small opacities with margins of the small opacities remaining visible, whereas a large opacity demonstrates a homogeneous opaque appearance. The symbol **ax** (coalescence of small opacities) may be recorded either in the presence or in the absence of large opacities.

¹¹ The symbol **id** (ill-defined diaphragm border) should be recorded only if more than one-third of one hemidiaphragm is affected.

¹² The symbol **ih** (ill-defined heart border) should be recorded only if the length of the heart border affected, whether on the right or on the left side, is more than one-third of the length of the left heart border.

| | |
|-----------|---|
| pa | plate atelectasis |
| pb | parenchymal bands ¹³ |
| pi | pleural thickening of an interlobar fissure ¹⁴ |
| px | pneumothorax |
| ra | rounded atelectasis |
| rp | rheumatoid pneumoconiosis ¹⁵ |
| tb | tuberculosis ¹⁶ |
| od | other disease or significant abnormality ¹⁷ |

3.5. Comments

If the technical quality of the radiograph is not recorded as **1** (good), then a Comment on why this is so should be made at that time, before proceeding with the classification.

Comments are also required if the symbol **od** (other disease) is recorded, and to identify any part of the reading of a chest radiograph which is believed by a reader to be probably or certainly not dust related.

Comments should also be recorded to provide other relevant information.

¹³ Significant parenchymal fibrotic strands in continuity with the pleura.

¹⁴ Illustrated on the **3/3 s/s** standard radiograph.

¹⁵ Illustrated on the **1/1 p/p** standard radiograph.

¹⁶ The symbol **tb** should be used for either suspect active or suspect inactive tuberculosis. The symbol **tb** should not be used for the calcified granuloma of tuberculosis or other granulomatous processes, e.g. histoplasmosis. Such appearances should be recorded as **cg**.

¹⁷ If the symbol **od** is used, then an explanatory Comment must be made.

Specific instructions for the use of the Abbreviated Classification

The Abbreviated Classification, described below, is a simplified version of the Complete Classification and includes its major components.

Technical quality

The recording of the technical quality of the radiograph is the same as for the Complete Classification (see section 3.1).

Small opacities

Profusion is determined by comparison with standard radiographs and recorded as one of the categories: **0, 1, 2** or **3** (see section 3.2).

Shape and size are determined by comparison with standard radiographs. The predominant shape and size are recorded using only one of the following letters: **p, q, r, s, t** or **u** (see section 3.2).

Large opacities

Large opacities are recorded as size **A, B** or **C**, in the same way as for the Complete Classification (see section 3.2).

Pleural abnormalities

All types of pleural thickening are recorded by the letters **PT**.

All types of pleural calcifications are recorded by the letters **PC**.

Symbols

Symbols are recorded as for the Complete Classification (see section 3.4).

Comments

Comments are recorded as for the Complete Classification (see section 3.5).

Using the ILO Classification

Efficient use of the ILO Classification requires good viewing and recording conditions. The following recommendations are particularly important for epidemiological studies.

Viewing

The illuminated boxes for viewing the radiographs to be classified and the standard radiographs must be close enough for the observer to see opacities only 1 mm in diameter, that is, a distance of about 250 mm. It is also essential to view the entire radiograph. The observer should be seated comfortably.

The minimum number of viewing spaces is two, allowing comparisons between the subject radiograph and the standard radiographs. However, it is recommended that three viewing spaces be used, so that the subject radiograph can be placed between the appropriate standard radiographs to assess profusion. It is important to make it easy to select and put up the standard radiographs for comparison, which is mandatory.

The viewing surfaces must be clean and the intensity of illumination should be uniform over all surfaces. The general illumination in the room should be low, without direct daylight. The room should be quiet, comfortable and free from distractions.

Epidemiological reading protocols

When classifying radiographs for epidemiological purposes, it is essential that the reader does not consider any other information about the individuals being studied. Awareness of supplementary details specific to individuals can introduce bias into results. If the epidemiological objective is to make comparisons between two or more groups, then the radiographs from all groups should be mixed and presented to the reader in random order. Failure to observe these principles may invalidate conclusions from the study.

Recording

Recording of results should be standardized and systematic. It is important to make provision for recording explicitly the presence or absence of all features to be evaluated for a particular study. Clerical help for recording results is valuable when

classifying large numbers of radiographs. The clerical assistant should be asked to remind the reader of failure to report the presence or absence of any features to be analysed in the study.

Reading rates

The number of radiographs classifiable per unit of time can vary greatly. Factors influencing reading rates include the technical quality of the radiographs, the prevalence of abnormalities on the radiographs, the experience of the reader, the purpose of the reading exercise and the length of the reading session.

Number of readers

It is recognized that there is considerable variation in multiple readings of some radiographs, not only from reader to reader (inter-observer variation), but also between readings by the same reader (intra-observer variation). It is recommended that, in epidemiological studies, at least two, but preferably more, readers each classify all radiographs independently.

When many radiographs are being read, intra-observer variation, i.e. variation in repeated readings by the same reader, should be assessed.

Using the ILO Classification to classify digital radiographic images of the chest

Purpose

The purpose of this chapter is to extend the applicability of the ILO International Classification of Radiographs of Pneumoconioses beyond conventional chest radiographs to digital radiographic images of the chest.

Introduction

Earlier editions of these *Guidelines* referred to postero-anterior chest radiographs and to comparisons of a subject's radiograph with ILO standard radiographs. Both subject and standard radiographs were obtained using film-screen radiography (FSR)¹. (Readers who have the film versions of the radiographs should note that the present revised Guidelines apply equally to the film and digital versions.) The revised (2000) edition of the *Guidelines* recognized that other imaging techniques may be required for clinical purposes, but noted that the ILO Classification was not designed to code findings from the application of such methods. As anticipated at that time, methods for imaging the chest for lung diseases have continued to evolve. Major advances during recent years have included widespread application of digital techniques which, under appropriately controlled conditions, allow classification of chest abnormalities in a manner consistent with classifications using FSR.

The remainder of this chapter provides guidance on how to classify digital images of the chest in a way that maintains continuity and consistency with the ILO (2000) Classification and its associated standard radiographs. The following paragraphs supplement earlier parts of this monograph which remain in effect for digital images, except as specifically noted below. Valid application of the ILO Classification to digital chest images requires users to adhere to all recommendations in this chapter, and to remain alert to future developments in digital chest imaging techniques.

¹ *FSR – Film-screen-radiography*. (Synonyms include chest radiograph, chest x-ray, conventional film-screen radiography. See also the Foreword to the present edition of these Guidelines (page vii) for notes on the nomenclature used in this chapter.)

ILO Standard Digital Images

Standard digital images corresponding to the ILO (2000) standard radiographs are now available from the ILO on electronic storage media. These ILO Standard Digital Images (ILO 2011 -D) define and illustrate the shapes, sizes and profusion of small opacities visible on digital images. The corresponding text in Chapter 3, above, provides supplementary information, but the appearances of the standard digital images take precedence for classification purposes. On the other hand, the standard digital images of large opacities and of pleural abnormalities represent examples of those features. Their size, location and other characteristics are defined in Chapter 3, and for classification purposes that text takes precedence.

Viewing principles

When viewing either the film-screen radiographs or hard copies² of digital images, valid classifications consistent with the ILO system require use of the ILO (2000) standard radiographs, as detailed in Chapters 3 through 5. Hard copies of digital images should not be reduced below two-thirds of a standard-sized image (14" x 17", or 35 cm x 43 cm).

When viewing and classifying a subject's soft copy³ digital image, the ILO (2011-D) standard digital images must be used. Subject and standard digital images should be displayed on medical-grade flat-panel monitors designed for diagnostic radiology. The diagonal display should be at least 21" (54 cm) per image, with a ratio of maximum to minimum luminance at least 50; a maximum luminance of at least 250 candelas per m²; pixel pitch no greater than 210 µm; and with resolution at least 2.5 line-pairs per mm.⁴ The subject and standard images should be displayed simultaneously, similarly sized, side-by-side.

Examples of approaches *not recommended* for viewing soft copies include:

- Displaying the images on a personal computer screen rather than on a medical-grade flat-panel monitor designed for diagnostic radiology;
- Comparing the subject digital image to ILO (2000) standard radiographs displayed on a view box;

² *Hard copy* – A hard copy is a digital image printed on transparent film in an attempt to reproduce the x-ray image in its original quality.

³ *Soft copy* – A soft copy is a digital image displayed on a monitor. For classification purposes, digital images should be displayed on medical-grade flat-panel monitors designed for diagnostic radiology.

⁴ Definitions and further explanations of technical terms, as well as other information relevant to digital radiography, can be found in publications by professional associations, standard-setting organizations and other agencies, for instance:

- (a) American College of Radiology. ACR Technical Standard for Electronic Practice of Medical Imaging, Res. 13-2007. In *ACR Practice Guidelines and Technical Standards*, pp. 1053–1067. ACR, Reston, VA, 2007.
- (b) American College of Radiology. Practice Guidelines for Digital Radiography, Res. 42-2007. In *ACR Practice Guidelines and Technical Standards*, pp. 23–57. ACR, Reston, VA, 2007.
- (c) *European Guidelines on Quality Criteria for Diagnostic Radiographic Images*. Report EUR 16260. European Commission. Luxembourg, Office for Official Publications of the European Communities, 1996.
- (d) *The 1991 CEC Trial on quality criteria for diagnostic radiographic images: Detailed results and findings*. Report EUR 16635. European Commission. Luxembourg, Office for Official Publications of the European Communities, 1999.
- (e) American Association of Physicists in Medicine. *Assessment of Display Performance for Medical Imaging Systems*. AAPM On-Line Report No. 03, Task Group 18. College Park, MD. April 2005.

- Viewing the subject digital image, or the ILO (2011-D) standard digital images (or both) in formats reduced to less than two-thirds of their full size; and
- Using images printed on paper for classification.

As with all radiographic viewing activities, procedures should be followed to ensure an appropriate environment, including restriction of ambient light sources and other distracting factors. (See page 12 of these *Guidelines*.)

Acquisition, display, and storage of digital chest images

Radiographic systems for collecting, displaying, and storing chest images for classification of pneumoconiosis should adhere to the most recent version of the Digital Imaging and Communications in Medicine (DICOM) standards or other comparable standards (for example, MEDICOM EN12052). The DICOM standards (<http://medical.nema.org>) are widely accepted and used internationally for radiographic imaging. They specify a common format for storage and transfer of digital images, and for brightness, contrast levels, and a consistent greyscale when presenting images on display monitors and printing digital images. Care should be taken to maintain image quality and consistency when producing hard copies of digital images.

Additional notes and recommendations⁵

Imaging equipment

Hardware for production of digital chest images is manufactured and distributed by many commercial entities with varying approaches to image capture. A group of systems based on storage-phosphor technology is described as computed radiography (CR). A second group of systems, known as digital radiography (DR), has become available more recently. Both are acceptable for application of the ILO Classification, with appropriate attention to image quality.

Image acquisition and processing

Digital radiographic systems vary in the approaches taken to address the display quality of digital chest images. Image processing software continues to evolve. No specific recommendations are made by the ILO regarding the selection of digital systems. Performance testing and monitoring should be used to evaluate the ability to produce quality images for any combination of hardware, exposure parameters and software. Facilities providing images for classification should employ a program for continual quality assurance consistent with national practices and standards. Staff at facilities that perform digital chest radiography for pneumoconiosis classification should review each image to ensure optimal quality.

⁵ See footnote 4.

Image display

Good image quality is essential for accurate classification of digital chest radiographs. Maintenance, assessment, and optimisation of the image display monitors and all other components of the digital radiographic systems should be undertaken periodically, as recommended or specified by manufacturers, professional organizations, or governmental agencies.⁶ While classifying digital images, the ILO (2011-D) Standard Digital Images should be displayed as provided, without alteration.⁷

Data recording, storage, and security

Digital images should be securely archived and transferred in a manner that permits retrieval of their original appearance, in compliance with national practices and standards. Standard measures to prevent unauthorized access to data should be employed, for instance by password-protected access and rigorous security precautions for transfers through data networks.

⁶ For example, see (a) and (c) in footnote 4.

⁷ The standard digital radiographs were chosen to demonstrate the radiographic features of the pneumoconioses, rather than technical quality.

Appendices

The appendices have been prepared by individual experts to assist understanding of the principles and development of the ILO International Classification. They are not part of the text of the ILO (2000) International Classification of Radiographs of Pneumonioses. The ILO wishes to express its gratitude to Dr. Kurt G. Hering, Dr. Yutaka Hosoda, Dr. Michael Jacobsen, Dr. Yukinori Kusaka, Mr. Otha W. Linton, Dr. John E. Parker, Dr. Anthony V. Proto, Dr. Hisao Shida, Dr. Gregory R. Wagner, Dr. Jerome F. Wiot and Dr. Anders Zitting for the preparation of the appendices.

Appendix A – A note on technical quality for chest radiographs of dust-exposed workers

It has long been recognized that the technique and equipment used for chest radiographic imaging of dust-exposed workers affect the radiographic appearance of pneumoconiotic lesions, and that this can influence the classification of a radiograph for pneumoconiosis. Both clinical interpretations of chest radiographs, and the use of the ILO Classification for medical screening, public health surveillance and epidemiological research, require good-quality radiographs. Consequently, readers may find it difficult to use the ILO Classification if the quality of chest radiographs is suboptimal. In some cases, it may be impossible to classify such a radiograph. Provision has been made for this contingency in section 3.1 of these *Guidelines* by the definition of technical quality grade 4 (“unacceptable for classification purposes”).

Common quality faults include *underexposure* (often associated with a tendency to read more profusion than would be recognized on an optimally produced radiograph) and *overexposure* (associated with the converse tendency). Experienced readers may sometimes adjust their assessments of such radiographs to compensate, to some extent, for these perceived technical faults. Nevertheless, physicians and radiographers should strive always to obtain good-quality radiographs.

An optimal radiographic technique for the assessment of pneumoconiosis should reveal the fine detail of parenchymal markings, demonstrate clearly the costal–pleural junctions and show vascular markings through the cardiac shadow. It should be noted, however, that good contrast, required to evaluate the pulmonary parenchyma, may be suboptimal for assessment of mediastinal structures.

Methods for imaging the chest for dust-related lung diseases continue to evolve as new technologies are introduced. In view of these ongoing developments, it would be inappropriate here to attempt to provide detailed technical advice on radiographic technique and equipment. Authoritative information on these topics may be found in a number of specialist publications. A select bibliography is provided at the end of this appendix.

These *Guidelines* require that a decision on whether a radiograph is of good, or at least of acceptable, technical quality rests ultimately with the physician who classifies the radiograph. Therefore, a key general principle must be the establishment and maintenance of good communication between the physician and the radiographer, so that high-quality images, providing an adequate view of the pulmonary parenchyma and pleura, are obtained. The radiographer must be well trained and supervised, and must work in a climate that invites dialogue with the physician/reader. The physician must provide feedback to the radiographer to ensure improvement of any suboptimal images, and should be prepared to advise on quality control for the production of chest radiographs of dust-exposed workers. Physicians and radiographers should take cognizance of local regulations.

Select bibliography

- American College of Radiology. *ACR Standard for the Performance of Pediatric and Adult Chest Radiography* (Reston, VA., American College of Radiology, 1997).
- Commission of the European Community. *European Guidelines on Quality Criteria for Diagnostic Radiographic Images*, edited by J.H.E. Carmichael et al. Report OP-EUR 16260 (Luxembourg, 1996).
- Guibelalde, E., et al. "Image quality and patient dose for different screen-film combinations", in *British Journal of Radiology*, Vol. 67, No. 794, Feb. 1994, pp.166–173.
- Holm, T.; Palmer, P.E.S.; Lehtinen, E. *Manual of radiographic technique: WHO Basic Radiological System*. (Geneva, World Health Organization, 1986).
- International Labour Office. "Appendix A. Equipment and technology: Guidance notes", prepared by H. Bohlig et al., in *Guidelines for the Use of ILO International Classification of Radiographs of Pneumoconioses*. Revised edition 1980 (Geneva), pp.21–25.
- Ravin, C.E.; Chotas, H.G. "Chest radiography", in *Radiology*, Vol. 204, No. 3 (Sept. 1997), pp. 593–600.

Appendix B – Reading sheets

The reading sheets on the following pages are examples of what may be used with the ILO (2000) International Classification of Radiographs of Pneumoconioses. In some situations, clinical or epidemiological, other designs may be preferred for specific uses. The sheets illustrated here make provision for recording all features described in the Complete Classification and the Abbreviated Classification. However, they are not a formal part of the ILO International Classification.

Shape and size : p, q, r, s, t or u
(Consult standard radiographs. Two symbols required ;

mark one primary and one secondary.)

Primary

p s
 q t
 r u

Secondary

P S
 Q T
 R U

0 A B C

Mark 0 for none or mark A, B, or C

Large opacities

PLEURAL ABNORMALITIES

(0=None R=Right L=Left)

PLEURAL PLAQUES

Site

(Mark appropriate boxes)

Calcification
(Mark)

| | | | | | | | | | |
|--------------------------|--------------------------|--------------------------|--------------------------|--------------------------|--------------------------|--------------------------|--------------------------|--------------------------|--------------------------|
| Chest wall in profile | <input type="checkbox"/> | <input type="checkbox"/> | <input type="checkbox"/> | <input type="checkbox"/> | <input type="checkbox"/> | <input type="checkbox"/> | <input type="checkbox"/> | <input type="checkbox"/> | <input type="checkbox"/> |
| face-on | <input type="checkbox"/> | <input type="checkbox"/> | <input type="checkbox"/> | <input type="checkbox"/> | <input type="checkbox"/> | <input type="checkbox"/> | <input type="checkbox"/> | <input type="checkbox"/> | <input type="checkbox"/> |
| Diaphragm | <input type="checkbox"/> | <input type="checkbox"/> | <input type="checkbox"/> | <input type="checkbox"/> | <input type="checkbox"/> | <input type="checkbox"/> | <input type="checkbox"/> | <input type="checkbox"/> | <input type="checkbox"/> |
| Other site(s) | <input type="checkbox"/> | <input type="checkbox"/> | <input type="checkbox"/> | <input type="checkbox"/> | <input type="checkbox"/> | <input type="checkbox"/> | <input type="checkbox"/> | <input type="checkbox"/> | <input type="checkbox"/> |

Yes No
If "No" go to *SYMBOLS

Extent (chest wall; combined for
in-profile and face-on)
up to 1/4 of lateral chest wall = 1
1/4 to 1/2 of lateral chest wall = 2
> 1/2 of lateral chest wall = 3

0 R 0 L
 1 2 3 1 2 3

Width (optional)
(3 mm minimum width required)

3 to 5 mm = a
5 to 10 mm = b
> 10 mm = c

R L
 a b c a b c

COSTOPHRENIC ANGLE OBLITERATION R L

| DIFFUSE PLEURAL THICKENING (Mark appropriate boxes) | Calcification (Mark) | Extent (chest wall; combined for in-profile and face-on) up to 1/4 of lateral chest wall = 1 1/4 to 1/2 of lateral chest wall = 2 > 1/2 of lateral chest wall = 3 | Width (optional) (3 mm minimum width required) 3 to 5 mm = a 5 to 10 mm = b > 10 mm = c |
|---|---|--|---|
| Chest wall in profile <input type="checkbox"/> R <input type="checkbox"/> L | <input type="checkbox"/> R <input type="checkbox"/> L | <input type="checkbox"/> R <input type="checkbox"/> L | <input type="checkbox"/> R <input type="checkbox"/> L |
| face-on <input type="checkbox"/> R <input type="checkbox"/> L | <input type="checkbox"/> R <input type="checkbox"/> L | 1 2 3 <input type="checkbox"/> 1 <input type="checkbox"/> 2 <input type="checkbox"/> 3 | a b c <input type="checkbox"/> a <input type="checkbox"/> b <input type="checkbox"/> c |

*SYMBOLS
 aa at bu ca cg cn co cp cv di ef em es Yes No
 fir hi ho id ih kl me pa pb pi px ra rp tb od Yes No

COMMENTS Yes No

(Circle as appropriate; if **od** circled, COMMENT must be made below)

**READING SHEET FOR
ABBREVIATED ILO (2000) INTERNATIONAL CLASSIFICATION OF RADIOGRAPHS OF PNEUMOCONIOSES**

| | | | |
|-----------------|---|-----------------------|---|
| READER CODE | <input style="width: 20px; height: 20px; border: 1px solid black;" type="text"/> <input style="width: 20px; height: 20px; border: 1px solid black;" type="text"/> <input style="width: 20px; height: 20px; border: 1px solid black;" type="text"/> | RADIOGRAPH IDENTIFIER | <input style="width: 20px; height: 20px; border: 1px solid black;" type="text"/> <input style="width: 20px; height: 20px; border: 1px solid black;" type="text"/> <input style="width: 20px; height: 20px; border: 1px solid black;" type="text"/> <input style="width: 20px; height: 20px; border: 1px solid black;" type="text"/> <input style="width: 20px; height: 20px; border: 1px solid black;" type="text"/> <input style="width: 20px; height: 20px; border: 1px solid black;" type="text"/> |
| DATE OF READING | <input style="width: 20px; height: 20px; border: 1px solid black;" type="text"/> <input style="width: 20px; height: 20px; border: 1px solid black;" type="text"/> <input style="width: 20px; height: 20px; border: 1px solid black;" type="text"/> <input style="width: 20px; height: 20px; border: 1px solid black;" type="text"/> <input style="width: 20px; height: 20px; border: 1px solid black;" type="text"/> <input style="width: 20px; height: 20px; border: 1px solid black;" type="text"/> <input style="width: 20px; height: 20px; border: 1px solid black;" type="text"/> <input style="width: 20px; height: 20px; border: 1px solid black;" type="text"/> <input style="width: 20px; height: 20px; border: 1px solid black;" type="text"/> <input style="width: 20px; height: 20px; border: 1px solid black;" type="text"/> | DATE OF RADIOGRAPH | <input style="width: 20px; height: 20px; border: 1px solid black;" type="text"/> <input style="width: 20px; height: 20px; border: 1px solid black;" type="text"/> <input style="width: 20px; height: 20px; border: 1px solid black;" type="text"/> <input style="width: 20px; height: 20px; border: 1px solid black;" type="text"/> <input style="width: 20px; height: 20px; border: 1px solid black;" type="text"/> <input style="width: 20px; height: 20px; border: 1px solid black;" type="text"/> <input style="width: 20px; height: 20px; border: 1px solid black;" type="text"/> <input style="width: 20px; height: 20px; border: 1px solid black;" type="text"/> |

TECHNICAL QUALITY
Grade 1, 2, 3 or 4

(Mark appropriate box)
If grade not 1, Comment required here

Comment on technical quality:

PARENCHYMAL ABNORMALITIES

Small opacities

Profusion (4-point scale)
(Consult standard radiographs — mark profusion category)

Predominant shape and size
(Consult standard radiographs) (Mark only one box)

| | | | | |
|--|--|--|--|--|
| <input style="width: 20px; height: 20px; border: 1px solid black;" type="text"/> | <input style="width: 20px; height: 20px; border: 1px solid black;" type="text"/> | <input style="width: 20px; height: 20px; border: 1px solid black;" type="text"/> | <input style="width: 20px; height: 20px; border: 1px solid black;" type="text"/> | <input style="width: 20px; height: 20px; border: 1px solid black;" type="text"/> |
| p | q | r | s | t |
| | | u | | |

Large opacities

Mark 0 for none
or mark A, B or C

PLEURAL ABNORMALITIES

(0 = None R = Right L = Left)

Yes No
 If "No" go to *SYMBOLS

Pleural thickening — PT R L

Pleural calcification — PC R L

***SYMBOLS**

aa at ax bu ca cg cn co cp cv di ef em es
 fr hi ho id ih kl me pa pb pi px ra rp tb od

Yes No

(Circle as appropriate; if **od** circled,
 COMMENT must be made below)

COMMENTS

Yes No

Appendix C – Description of standard radiographs

The Complete Set (22 radiographs)

The ILO (2000) International Classification of Radiographs of Pneumoconioses is accompanied by 22 standard radiographs. Two of them illustrate category **0/0** profusion of small opacities. Fifteen others define small-opacity profusion categories (**1/1**, **2/2** and **3/3**), and some of the shapes and sizes of these opacities (**p**, **q**, **r**, **s**, and **t**). Large opacities (categories **A**, **B** and **C**) are shown on three additional radiographs. These 20 radiographs are described in the following table using the conventions defined in the preceding text and including Comments. The site of small opacities is shown by a tick in the boxes symbolizing the zones of the lungs, as follows:

| | Right | Left |
|--------|--------------------------|--------------------------|
| Upper | <input type="checkbox"/> | <input type="checkbox"/> |
| Middle | <input type="checkbox"/> | <input type="checkbox"/> |
| Lower | <input type="checkbox"/> | <input type="checkbox"/> |

The two remaining standard radiographs are composite reproductions of sections from full-size chest radiographs. One depicts increasing profusion of irregular small **u**-sized opacities. The other illustrates various pleural abnormalities.

The radiographs that define the small-opacity profusion categories are copies of the same standards that were published in 1980, thus preserving continuity and consistency in the Classification. As noted in footnote 3 on page 3, the standard radiographs were chosen to demonstrate the radiographic features of the pneumoconioses, rather than to demonstrate technical quality.

The descriptions of the radiographs in the following table are the consensus views of a group of experts who reassessed the standards in the year 2000. These descriptions differ in some respects from those published in the earlier (1980) edition of the Classification. Judgements about the technical quality of the radiographs reflect familiarity with current optimal techniques and thus may appear more severe, with only six graded **1** (good). Descriptions of pleural abnormalities now follow the modified conventions that are defined in these *Guidelines* (section 3.3). The Comments in the right-hand column of the table include some additional observations by the reviewers.

The Quad Set (14 radiographs)

Also available from the ILO is a set of 14 standard radiographs that are wholly compatible with the Complete Set referred to above.¹ The Quad Set may be preferred by some users of the Classification. It includes nine of the most commonly used standard radiographs from the Complete Set (both category **0/0** examples, six showing categories **1/1**, **2/2** and **3/3** for **q/q** and **t/t** small opacities, and the composite radiograph that illustrates pleural abnormalities). The remaining five radiographs in the Quad Set are composite reproductions of quadrant sections from the other radiographs in the Complete Set. Four of them show different profusion categories for small opacities classifiable as **p/p**, **r/r**, **s/s** and **u/u**, respectively, and one shows large opacities (categories **A**, **B** and **C**).

Scientific reports that mention these *Guidelines* and the associated standard radiographs should refer to them explicitly as the ILO (2000) International Classification of Radiographs of Pneumoconioses, to avoid confusion with earlier editions of the Classification and copies of standard radiographs. The international trial, which demonstrated the general compatibility of the Quad Set with the Complete Set, showed that, when using the Quad Set, some readers identified large opacities less frequently than when they used the Complete Set. Use of the Quad Set was also associated with an increase in the frequency with which some readers described the shapes of the small opacities that they saw as predominantly irregular, rather than rounded. It is recommended, therefore, that authors of research reports should indicate which set of standard radiographs (the Complete Set or the Quad Set) was used in their studies.

¹ See footnote 1 in the foreword.

Description of standard radiographs

| Standard radiograph (ILO, 2000) | Technical Quality | Parenchymal abnormalities | | | | Pleural abnormalities | | | | Symbols | Comments |
|---------------------------------|-------------------|---------------------------|----------------|--|-----------------|--|----------------------------|-----------|--|---------|--|
| | | Profusion | Shape and size | Zones | Large opacities | Chest wall | | Diaphragm | Calcification | | |
| | | | | | | Plaques (localized pleural thickening) | Diffuse pleural thickening | | | | |
| 1/1 q/q | 2 | 1/1 | q/q | R L <input checked="" type="checkbox"/> <input checked="" type="checkbox"/> | No | No | No | No | No | None | Quality: overexposed; costophrenic angles excluded. |
| 2/2 q/q | 1 | 2/2 | q/q | R L <input checked="" type="checkbox"/> <input checked="" type="checkbox"/> | No | No | No | No | Yes R L <input type="checkbox"/> <input checked="" type="checkbox"/> | None | Right costophrenic angle appearance due to muscle slip. |
| 3/3 q/q | 2 | 3/3 | q/q | R L <input checked="" type="checkbox"/> <input checked="" type="checkbox"/> | No | No | No | No | No | pi | Quality: underexposed; costophrenic angle excluded. |
| 1/1 r/r | 2 | 1/1 | r/r | R L <input checked="" type="checkbox"/> <input checked="" type="checkbox"/> | No | No | No | No | Yes R L <input type="checkbox"/> <input checked="" type="checkbox"/> | None | Quality: scapular overlap; unsharp lower zones. Profusion of small opacities is more marked in right lung. |
| 2/2 r/r | 2 | 2/2 | r/r | R L <input checked="" type="checkbox"/> <input checked="" type="checkbox"/> | No | No | No | No | No | hi | Quality: contrast too high. hi in right paratracheal area; evaluate. |

Description of standard radiographs

| Standard radiograph (ILO, 2000) | Technical Quality | | Parenchymal abnormalities | | | | Pleural abnormalities | | | | Symbols | Comments | | |
|---------------------------------|-------------------|-----|---------------------------|----------------|-------|---|-----------------------|------------|-----------|---------------------------------|---------|----------|---------------|--|
| | 2 | 3/3 | Profusion | Shape and size | Zones | | Large opacities | Chest wall | Diaphragm | Costophrenic angle obliteration | | | Calcification | |
| | | | | | R | L | | | | | | | | Plaques (localized pleural thickening) |
| 3/3 r/r | 2 | 3/3 | r/r | | | | | | | | | | | Quality: contrast too high. ax in right upper zone. |
| | | | | | | | | | | | | | | |
| 1/1 s/t | 2 | 1/1 | s/t | | | | | | | | | | | Quality: unsharp areas; costophrenic angles excluded. |
| | | | | | | | | | | | | | | |
| 2/2 s/s | 2 | 2/2 | s/s | | | | | | | | | | | Quality: slightly underexposed; costophrenic angles excluded. em in upper zones. pb in left lower zone. |
| | | | | | | | | | | | | | | |
| 3/3 s/s | 2 | 3/3 | s/s | | | | | | | | | | | Quality: slightly underexposed; scapular overlap. ho at right costophrenic angle ih pi See footnote 14 on page 9. |

Description of standard radiographs

| Standard radiograph (ILO, 2000) | Technical Quality | Parenchymal abnormalities | | | | Pleural abnormalities | | | | Symbols | Comments | |
|---------------------------------|-------------------|---------------------------|----------------|-------------------------------------|-------------------------------------|-----------------------|--|----------------------------|-----------|-------------------------------------|--------------------------|---|
| | | Profusion | Shape and size | Zones | | Large opacities | Chest wall | | Diaphragm | | | Calcification |
| | | | | R | L | | Plagues (localized pleural thickening) | Diffuse pleural thickening | | | | |
| 1/1 t/t | 2 | 1/1 | t/t | R | L | No | No | Yes | No | Yes | None | Quality: scapular overlap on right, but visualization of lung and pleura not compromised. |
| Costophrenic angle obliteration | | | | <input type="checkbox"/> | <input type="checkbox"/> | No | No | R | L | R | L | This radiograph defines the lower limit of costophrenic angle obliteration. Calcified face-on plaques at lower and mid-left chest wall. |
| | | | | <input checked="" type="checkbox"/> | <input checked="" type="checkbox"/> | No | No | R | L | <input checked="" type="checkbox"/> | <input type="checkbox"/> | |
| | | | | <input checked="" type="checkbox"/> | <input checked="" type="checkbox"/> | No | No | face-on | | | | |
| 2/2 t/t | 1 | 2/2 | t/t | R | L | No | No | No | No | No | None | |
| | | | | <input checked="" type="checkbox"/> | <input checked="" type="checkbox"/> | No | No | | | | | |
| | | | | <input checked="" type="checkbox"/> | <input checked="" type="checkbox"/> | No | No | | | | | |
| | | | | <input checked="" type="checkbox"/> | <input checked="" type="checkbox"/> | No | No | | | | | |
| 3/3 t/t | 1 | 3/3 | t/t | R | L | No | No | No | No | No | ca cp ho id ih od | ca: superior to left hilum. ho: best seen at left lower zone. od: nodule lateral to left hilum. |
| | | | | <input checked="" type="checkbox"/> | <input checked="" type="checkbox"/> | No | No | | | | | |
| | | | | <input checked="" type="checkbox"/> | <input checked="" type="checkbox"/> | No | No | | | | | |
| | | | | <input checked="" type="checkbox"/> | <input checked="" type="checkbox"/> | No | No | | | | | |
| 0/0 | — | — | — | — | — | — | — | — | — | — | — | This composite radiograph |
| 1/1 u/u | — | — | — | — | — | — | — | — | — | — | — | illustrates central subcategories |
| 2/2 u/u | — | — | — | — | — | — | — | — | — | — | — | of profusion of small opacities |
| 3/3 u/u | — | — | — | — | — | — | — | — | — | — | — | classifiable for shape and size as u/u. |

Description of standard radiographs

| Standard radiograph (ILO, 2000) | Technical Quality | | Parenchymal abnormalities | | | Pleural abnormalities | | | | Symbols | Comments | | |
|---------------------------------|-------------------|----------------|---------------------------|-------|------------------|-----------------------|---------------------------------------|----------------------------|---------------------------------|---------|----------|----------------------|---|
| | Profusion | Shape and size | Shape and size | Zones | Large opacities | Chest wall | Plaque (localized pleural thickening) | Diffuse pleural thickening | Costophrenic angle obliteration | | | Diaphragm | Calcification |
| A | 2 | 2/2 | p/q | R L A | ✓ ✓ ✓ ✓ | No | No | No | No | No | No | None | Quality: high contrast; right scapular overlap obscures visualization. If concerned that right upper zone opacity could be cancer, add symbol ca. |
| B | 1 | 1/2 | q/p | R L B | ✓ ✓ ✓ | No | No | No | No | No | No | ax ca | ca: right lateral mid-zone nodule. |
| C | 1 | 2/1 | q/t | R L C | ✓ ✓ ✓ | No | No | No | No | No | No | ax em es ih | bu at right upper zone. em best seen at left lower zone; es at hilar and azygos node. Small opacities difficult to classify in the presence of large opacities. |

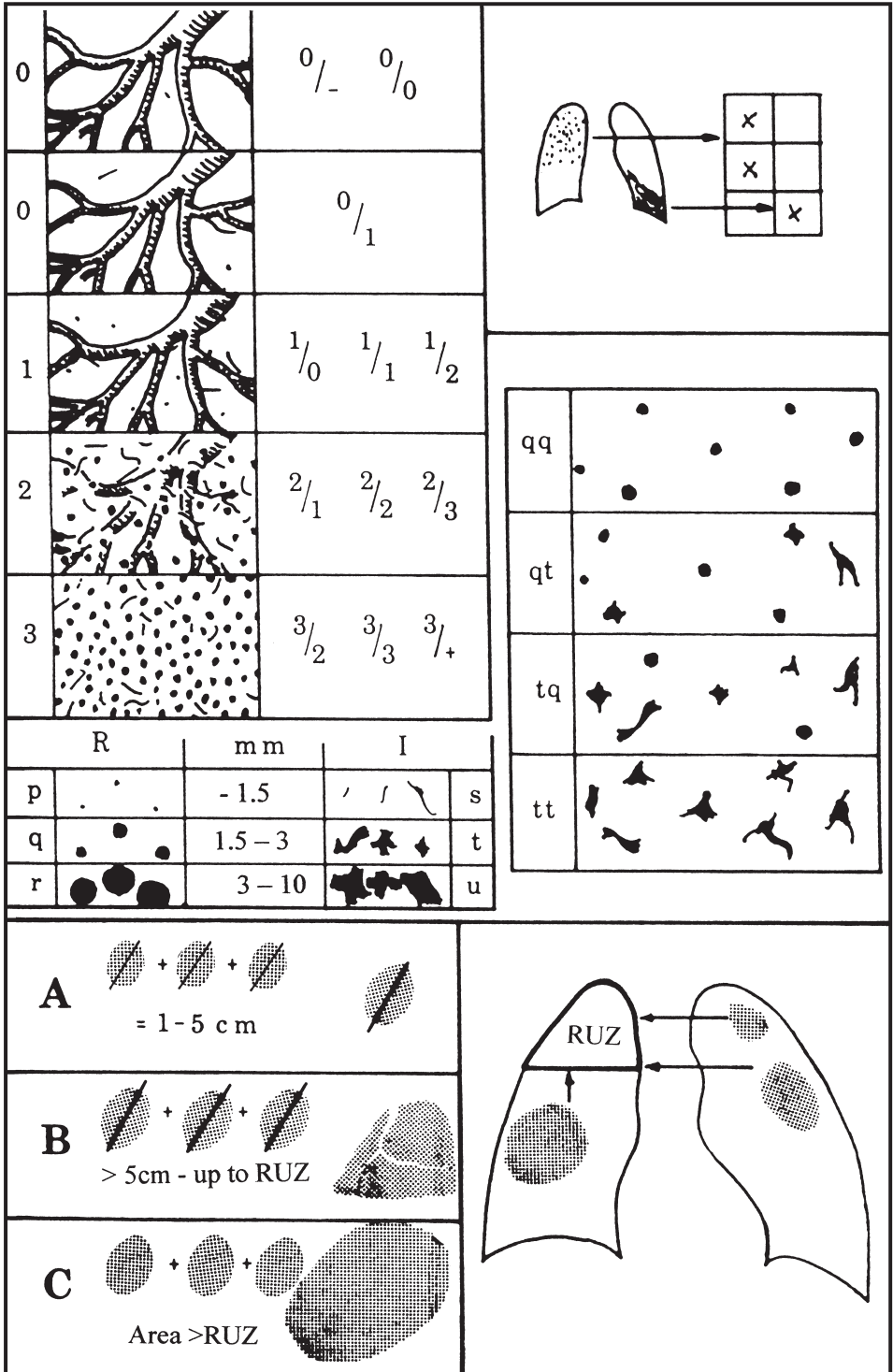
ILO (2000) Composite standard radiograph showing examples of pleural abnormalities

| | |
|--|--|
| Upper-left section: calcified plaques at diaphragm | Upper-right section: calcified in-profile and face-on plaques |
| Lower-left section: diffuse in-profile pleural thickening with the required costophrenic angle obliteration; also diffuse face-on pleural thickening | Lower-right section: calcified and uncalcified face-on plaques |

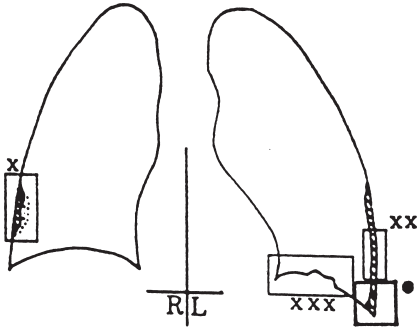
Appendix D – Diagrams

The diagrams on the following pages represent illustrations of radiographic features that are included in the Complete Classification. Those features are defined in the text of these *Guidelines* and by the appearances on the standard radiographs. The diagrams are intended to serve as pictorial reminders, but they are not a substitute for the standard radiographs or the written text.

Diagrams that represent symbols do not illustrate all the manifestations of the conditions defined by these symbols, for example **ca** (carcinoma), **cg** (calcified granuloma), **od** (other disease). The two drawings of appearances classifiable as **od** in this appendix represent lobar pneumonia and aspergilloma, goiter and hiatal hernia.



**Pleural abnormalities -
(localized and diffuse pleural thickening):**



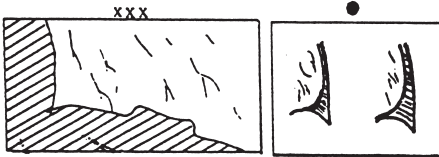
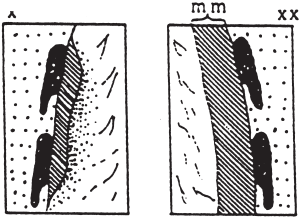
Extent:

- 0 = 0
- 1 = up to 1/4
- 2 = 1/4 - 1/2
- 3 > 1/2

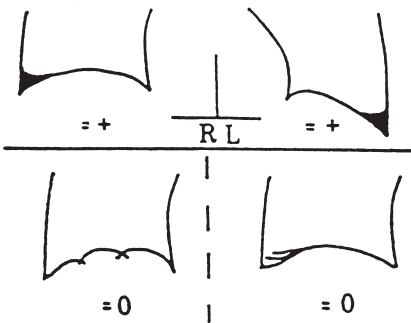
Width:

- a = 3-5 mm
- b = 5-10 mm
- c = > 10 mm

See Text!

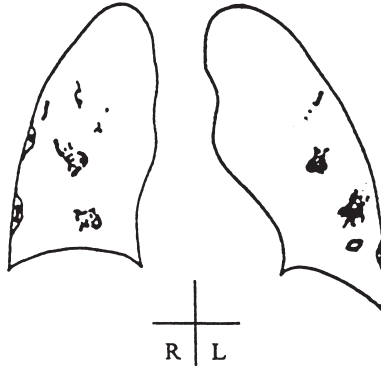


Costophrenic angle:

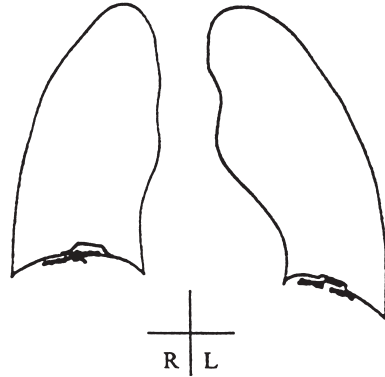


Pleural calcification:

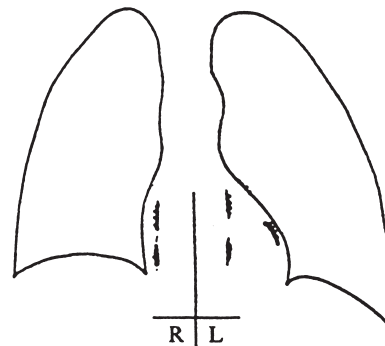
Chest wall


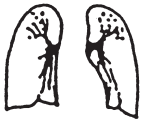




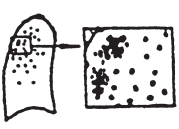
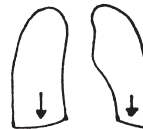


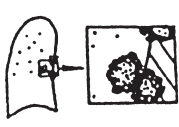







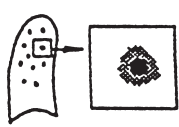













Diaphragm



Other sites



| | | | | | |
|----|---|----|---|----|--|
| aa |  | di |  | me |  |
| at |  | ef |  | pa |  |
| ax |  | em |  | pb |  |
| bu |  | es |  | pi |  |
| ca |  | fr |  | px |  |
| cg |  | hi |  | ra |  |
| cn |  | ho |  | rp |  |
| co |  | id |  | tb |  |
| cp |  | ih |  | od |  |
| cv |  | kl |  | od |  |

Appendix E – Summary of details of the ILO (2000) International Classification of Radiographs of Pneumoconioses

| Features | Codes | Definitions |
|----------------------------------|-------|--|
| TECHNICAL QUALITY | | |
| 1 | | Good. |
| 2 | | Acceptable, with no technical defect likely to impair classification of the radiograph for pneumoconiosis. |
| 3 | | Acceptable, with some technical defect but still adequate for classification purposes. |
| 4 | | Unacceptable for classification purposes. If technical quality is not grade 1, a comment must be made about the technical defect. |
| PARENCHYMAL ABNORMALITIES | | |
| Small opacities | | |
| Profusion | | |
| 0/- | 0/0 | 0/1 |
| 1/0 | 1/1 | 1/2 |
| 2/1 | 2/2 | 2/3 |
| 3/2 | 3/3 | 3/+ |
| Zones | | |
| | RU | LU |
| | RM | LM |
| | RL | LL |
| Shape and size | | |
| — rounded | | |
| | p/p | q/q r/r |
| — irregular | | |
| | s/s | t/t u/u |

| Features | Codes | Definitions |
|--|--|--|
| — mixed | p/s p/t p/u p/q p/r q/s q/t q/u q/p q/r r/s r/t r/u r/p r/q s/p s/q s/r s/t s/u t/p t/q t/r t/s t/u u/p u/q u/r u/s u/t | For mixed shapes (or sizes) of small opacities, the predominant (primary) shape and size is recorded first. The presence of a significant number of another shape and size (secondary) is recorded after the oblique stroke. |
| Large opacities | 0 A B C (0 = no large opacities) | One large opacity is defined as an opacity having the longest dimension exceeding 10 mm. Categories of large opacities are defined below. These definitions take precedence over the examples of large opacities illustrated on standard radiographs. Category A: one large opacity having the longest dimension up to about 50 mm, or several large opacities with the sum of their longest dimensions not exceeding about 50 mm. Category B: one large opacity having the longest dimension exceeding 50 mm but not exceeding the equivalent area of the right upper zone, or several large opacities with the sum of their longest dimensions exceeding 50 mm but not exceeding the equivalent area of the right upper zone. Category C: one large opacity which exceeds the equivalent area of the right upper zone, or several large opacities which when combined exceed the equivalent area of the right upper zone. |
| PLEURAL ABNORMALITIES | | |
| Pleural plaques (localized pleural thickening) | | Three types of pleural abnormalities are recognized: pleural plaques (localized pleural thickening), costophrenic angle obliteration and diffuse pleural thickening. These abnormalities are recorded as absent (0) or present. If present they are recorded separately for the right (R) and left (L) sides. |
| Chest wall in-profile | 0 R L | Pleural plaques on the chest wall are recorded separately as "in-profile" or "face-on". A minimum width of about 3 mm is required for an in-profile plaque to be recorded as present. The presence or absence of calcification is also noted separately for in-profile and face-on plaques. When calcification is seen, a plaque is also recorded as present at that site. For optional recording of width of an in-profile plaque, see footnote 8 on page 6. |
| — calcification | 0 R L | |
| — width (optional) | R(a, b, c) L(a, b, c) | |
| face-on | 0 R L | |
| — calcification | 0 R L | |
| extent | R(1, 2, 3) L(1, 2, 3) | Extent refers to the total length of involvement with respect to the projection of the lateral chest wall for in-profile and face-on plaques combined: 1 = total length up to 1/4 of the projection of the lateral chest wall; 2 = total length exceeding 1/4 and up to 1/2 of the projection of the lateral chest wall; and 3 = total length exceeding 1/2 of the projection of the lateral chest wall. |
| Diaphragm | 0 R L | When calcification is seen, a plaque is also recorded at that site. |
| — calcification | 0 R L | Other sites include the mediastinal pleura in the para-spinal or para-cardiac locations. |
| Other sites | 0 R L | When calcification is seen, a plaque is also recorded at that site. |
| — calcification | 0 R L | |

| Features | Codes | Definitions |
|---------------------------------|--|---|
| Costophrenic angle obliteration | 0 R L | The lower limit for costophrenic angle obliteration is defined by the standard radiograph showing profusion category $\frac{1}{4}$ to $\frac{1}{2}$. |
| Diffuse pleural thickening | 0 R L 0 R L R(a, b, c) L(a, b, c) 0 R L 0 R L R(1, 2, 3) L(1, 2, 3) | Diffuse pleural thickening extending up the lateral chest wall is recorded only in the presence of an obliterated costophrenic angle. If present, diffuse pleural thickening is recorded separately for the right and left sides when seen in-profile and when seen face-on. The presence or absence of calcification is noted in both cases. For optional recording of width of in-profile diffuse pleural thickening, see footnote 8 on page 6. |
| Chest wall | | Extent refers to the total length of involvement with respect to the projection of the lateral chest wall for in-profile and face-on varieties combined: |
| in-profile | | 1 = total length up to $\frac{1}{4}$ of the projection of the lateral chest wall; |
| — calcification | | 2 = total length exceeding $\frac{1}{4}$ and up to $\frac{1}{2}$ of the projection of the lateral chest wall; and |
| — width (optional) | | 3 = total length exceeding $\frac{1}{2}$ of the projection of the lateral chest wall. |
| face-on | | |
| — calcification | | |
| extent | | |
| SYMBOLS | | |
| aa | | The definition of each symbol should be understood as being preceded by an introductory qualifying word or phrase such as "changes indicative of", "opacities suggestive of", or "suspect". |
| at | | atherosclerotic aorta |
| ax | | significant apical pleural thickening |
| bu | | coalescence of small opacities |
| ca | | bullae |
| cg | | cancer: thoracic malignancies excluding mesothelioma |
| cn | | calcified non-pneumococcal nodules (e.g. granuloma) or nodes |
| co | | calcification in small pneumococcal opacities |
| cp | | abnormality of cardiac size or shape |
| cv | | cor pulmonale |
| di | | cavity |
| ef | | marked distortion of an intrathoracic structure |
| em | | pleural effusion |
| es | | emphysema |
| fr | | eggshell calcification of hilar or mediastinal lymph nodes |
| hi | | fractured rib(s) (acute or healed) |
| ho | | enlargement of non-calcified hilar or mediastinal lymph nodes |
| id | | honeycomb lung |
| ih | | ill-defined diaphragm border |
| kl | | ill-defined heart border |
| me | | septal (Kerley) lines |
| pa | | mesothelioma |
| pb | | plate atelectasis |
| pi | | parenchymal bands |
| px | | pleural thickening of an interlobar fissure |
| | | pneumothorax |

| Features | Codes | Definitions |
|--|-----------|---|
| rounded atelectasis | ra | rounded atelectasis |
| rheumatoid pneumoconiosis | rp | rheumatoid pneumoconiosis |
| tuberculosis | tb | tuberculosis |
| other disease or significant abnormality | od | other disease or significant abnormality |
| COMMENTS | Y (= Yes) | In addition to comments about the technical quality of the radiograph (see above), comments are also required if the symbol od (other disease) is recorded, and to identify any part of the reading of a chest radiograph which is believed by a reader to be probably or certainly not dust related. Comments should also be recorded to provide other relevant information. |
| | N (= No) | |

Appendix F – Participants in ILO- convened meetings leading to the revised (2000 and 2011) editions of the Classification

Meeting of Discussion Group at ILO Headquarters, Geneva, 6–7 November 1989

Participants

Professor P. Bartsch, Institut E. Malvoz, Liège, Belgium
Dr. Heinz Bohlig, Dormagen-Zons, Germany
Dr. Kurt G. Hering, Knappschafts Krankenhaus, Dortmund, Germany
Dr. Yutaka Hosoda, Radiation Effects Research Foundation, Japan
Dr. Matti Huuskonen, Finnish Institute of Occupational Health, Helsinki, Finland
Dr. Michael Jacobsen, Institute of Occupational Medicine, Edinburgh, United Kingdom
Mr. Otha Linton, American College of Radiology Task Force on Pneumoconiosis, Reston,
Virginia, United States
Professor Shixuan Lu, Institute of Occupational Health, Beijing, China
Professor Charles E. Rossiter, Harrow, United Kingdom
Dr. Gregory R. Wagner, National Institute for Occupational Safety and Health (NIOSH),
Morgantown, West Virginia, United States
Professor Jerome F. Wiot, University of Cincinnati Medical School, Cincinnati, Ohio,
United States

ILO Secretariat

Dr. Kazutaka Kogi
Dr. Georges H. Coppée
Dr. Alois David
Dr. Michel Lesage

Meeting of Discussion Group in Kyoto, Japan, 15–16 October 1997

Participants

- Dr. Kurt G. Hering, Knappschafts Krankenhaus, Dortmund, Germany
Dr. Yutaka Hosoda, Radiation Effects Research Foundation, Japan
Dr. Michael Jacobsen, Institute for Occupational and Social Medicine, University of Cologne, Germany
Professor Yukinori Kusaka, Fukui Medical University, Japan
Mr. Otha Linton, Potomac, Massachusetts, United States
Dr. John E. Parker, National Institute for Occupational Safety and Health (NIOSH), Morgantown, West Virginia, United States
Dr. Anthony V. Proto, Committee on Pneumoconiosis, American College of Radiology, Reston, Virginia, United States
Professor Hisao Shida, Rosai Hospital for Silicosis, Tochigi, Japan
Dr. Gregory R. Wagner, National Institute for Occupational Safety and Health (NIOSH), Morgantown, West Virginia, United States
Professor Jerome F. Wiot, University of Cincinnati Medical School, Cincinnati, Ohio, United States
Dr. Anders J. Zitting, Finnish Institute of Occupational Health, Helsinki, Finland

ILO Secretariat

- Dr. Georges H. Coppée
Dr. Igor Fedotov

Meeting of Discussion Group at the Office of the American College of Radiology, Reston, Virginia, United States, 20–21 March 1998

Participants

- Dr. Kurt G. Hering, Knappschafts Krankenhaus, Dortmund, Germany
Dr. Yutaka Hosoda, Radiation Effects Research Foundation, Japan
Dr. Michael Jacobsen, Institute for Occupational and Social Medicine, University of Cologne, Germany
Professor Yukinori Kusaka, Fukui Medical University, Japan
Mr. Otha Linton, Potomac, Maryland, United States
Dr. John E. Parker, National Institute for Occupational Safety and Health (NIOSH), Morgantown, West Virginia, United States
Dr. Anthony V. Proto, Committee on Pneumoconiosis, American College of Radiology, Reston, Virginia, United States
Professor Hisao Shida, Rosai Hospital for Silicosis, Tochigi, Japan

Dr. Gregory R. Wagner, National Institute for Occupational Safety and Health (NIOSH),
Morgantown, West Virginia, United States
Professor Jerome F. Wiot, University of Cincinnati Medical School, Cincinnati, Ohio,
United States
Dr. Anders J. Zitting, Finnish Institute of Occupational Health, Helsinki, Finland

ILO Secretariat

Dr. Igor Fedotov

Meeting of Discussion Group at the ILO Branch Office, Washington, DC, United States, 26 October 2000

Participants

Dr. Kurt G. Hering, Knappschafts Krankenhaus, Dortmund, Germany
Dr. Yutaka Hosoda, Radiation Effects Research Foundation, Japan
Professor Michael Jacobsen, Institute for Occupational and Social Medicine, University
of Cologne, Germany
Professor Yukinori Kusaka, Fukui Medical University, Japan
Mr. Otha Linton, Potomac, Maryland, United States
Professor John E. Parker, Pulmonary and Critical Care Medicine, West Virginia Univer-
sity, Morgantown, West Virginia, United States
Dr. Anthony V. Proto, Committee on Pneumoconiosis, American College of Radiology,
Reston, Virginia, United States
Professor Hisao Shida, Rosai Hospital for Silicosis, Tochigi, Japan
Dr. Gregory R. Wagner, National Institute for Occupational Safety and Health (NIOSH),
Morgantown, West Virginia, United States
Dr. Anders J. Zitting, Helsinki, Finland

ILO Secretariat

Dr. Benjamin O. Alli

Meeting of Panel on revision of the ILO (2000) Classification of Radiographs of Pneumoconioses in Rockville, Maryland, United States, 13–14 March 2008

Participants

Dr. Eduardo Algranti, Occupational Health Division, FUNDACENTRO, São Paulo,
Brazil

- Professor Jacques Ameille, AP-HP, Occupational Health Unit, Hôpital Raymond Poincaré, Garches, France
- Dr. Michael Attfield, National Institute for Occupational Safety and Health (NIOSH), Morgantown, West Virginia, United States
- Dr. Joseph E. Burkhardt, National Institute for Occupational Safety and Health (NIOSH), Morgantown, West Virginia, United States
- Dr. A. Franzblau, University of Michigan School of Public Health, Ann Arbor, Michigan, United States
- Dr. Daniel A. Henry, Department of Radiology, Medical College of Virginia Hospitals, Virginia Commonwealth University, Richmond, Virginia, United States
- Dr. Kurt G. Hering, Knappschafts Krankenhaus (Miners' Hospital), Dortmund, Germany
- Professor Michael Jacobsen, Ulverston, United Kingdom
- Professor Yukinori Kusaka, Fukui Medical University, Fukui, Japan
- Professor John E. Parker, Pulmonary and Critical Care Medicine, West Virginia University, Morgantown, West Virginia, United States
- Dr. Edward L. Petsonk, National Institute for Occupational Safety and Health (NIOSH), Morgantown, West Virginia, United States
- Dr. Ralph T. Shipley, University of Cincinnati College of Medicine, Cincinnati, Ohio, United States
- Professor Narufumi Suganuma, Department of Environmental Medicine, Kochi Medical School, Kochi University, Kochi, Japan
- Dr. Gregory R. Wagner, National Institute for Occupational Safety and Health (NIOSH), Washington, DC, United States
- Dr. David N. Weissman, National Institute for Occupational Safety and Health (NIOSH), Morgantown, West Virginia, United States

ILO Secretariat

Dr. Igor Fedotov

Film readers who participated in the international film-reading trial of new composite standard radiographs (the “Quad” trial), 1992–95

Canada

Dr. Raymond Bégin, Faculté de médecine, Université de Sherbrooke, Québec
Dr. Marc Desmeules, Hôpital Laval Centre de pneumologie, Ste-Foy, Québec
Dr. W. Keith C. Morgan, Chest Diseases Unit, University of Western Ontario, London, Ontario
Dr. David C. F. Muir, Health Sciences Center, McMaster University, Hamilton, Ontario

China

Dr. Guowei Li, Zhaoyang Red Cross Hospital, Beijing
Dr. Shunging Liu, Chendu Peoples' Hospital, Chendu
Dr. Yulin Liu, Institute of Industrial Health, Anshan Liaoning
Professor Cuijuan Zhang, National Institute of Occupational Medicine, Beijing

Czech Republic¹

Professor Alois David, Postgraduate Medical School, Prague
Dr. Jiří Slepíčka, Faculty Hospital, Ostrava
Dr. František Staník, Department of Occupational Diseases, Miners' Hospital, Karviná

Finland

Dr. Marja-Liisa Kokko, Tampere City Hospital, Tampere
Dr. Ossi Korhola, Helsinki University Central Hospital, Helsinki
Dr. Kristina M. Virkola, Helsinki University Children's Hospital, Helsinki
Dr. Anders J. Zitting, Finnish Institute of Occupational Health, Helsinki

France

Professor Jacques Ameille, Université Paris V, Faculté de médecine Paris Ouest, Garches
Professor Patrick Brochard, Université Bordeaux II, Bordeaux
Professor Dominique Choudat, Université Paris V, Faculté de médecine Cochin, Paris
Professor Marc Letourneux, Université de Caen

Germany

Dr. Kurt G. Hering, Knappschafts Krankenhaus, Dortmund
Dr. Peter Rathjen, Knappschafts Krankenhaus, Dortmund
Dr. Klaus Siegmund, Institut für Arbeitsmedizin der Heinrich-Heine-Universität, Düsseldorf
Dr. Volkmar Wiebe, Berufgenossenschaftliche Krankenanstalten, Universitätsklinik, Bochum

¹ As of 1 January 1993. Prior to that date, Czechoslovakia.

Japan

Dr. Keizo Chiyotani, Rosai Hospital for Silicosis, Tochigi
Professor Yukinori Kusaka, Fukui Medical University, Fukui
Dr. Hiroshi Morikubo, Rosai Hospital for Silicosis, Tochigi
Professor Hisao Shida, Rosai Hospital for Silicosis, Tochigi

Poland

Professor Aleksandra Kujawska, Institute of Occupational Medicine and Environmental Health, Sosnowiec
Professor Kazimierz Marek, Institute of Occupational Medicine and Environmental Health, Sosnowiec
Dr. Aleksander Stachura, Institute of Occupational Medicine and Environmental Health, Sosnowiec
Dr. Andrzej Stasiow, Hospital Ward and Outpatient Clinic for Occupational Diseases in Coalminers, Katowice-Ochojec

Slovakia¹

Professor Ladislav Benický, Medical Faculty, Košice

United Kingdom

Dr. Douglas Scarisbrick, British Coal Corporation Radiological Service, Mansfield Woodhouse, Nottinghamshire
Professor Anthony Seaton, Department of Environmental and Occupational Medicine, Aberdeen University, Aberdeen
Dr. Colin A. Soutar, Institute of Occupational Medicine, Edinburgh
Dr. Paul Willdig, British Coal Corporation Radiological Service, Mansfield Woodhouse, Nottinghamshire

United States

Professor N. LeRoy Lapp, Pulmonary and Critical Care Medicine, West Virginia University, Morgantown, West Virginia
Dr. Steven Short, Manhattan, Kansas
Dr. Mei-Lin Wang, Morgantown, West Virginia
Dr. Susan Weber, Pulmonary and Critical Care Medicine, West Virginia University, Morgantown, West Virginia

¹ As of 1 January 1993. Prior to that date, Czechoslovakia.